ACTA BIOLÓGICA COLOMBIANA
http://www.revistas.unal.edu.co/index.php/actabiol

Facultad de Ciencias
Departamento de Biología
Sede Bogotá

UNIVERSIDAD NACIONAL DE COLOMBIA

Research article

Occurrence of camallanids (Nematoda: Camallanidae) in fish hosts from the Peruvian Amazonia

Ocurrencia de camalánidos (Nematoda: Camallanidae) en peces hospedadores de la Amazonía peruana

German Augusto Murrieta Morey[1,2], Alana Lislea de Sousa[2], Diego Carvalho Viana[2,3], José Lisbinio Cruz Guimaraes[4], Victor Puicón Niño de Guzmán[5*]

[1] Instituto de Investigaciones de la Amazonía Peruana (IIAP), Iquitos, Perú. Laboratorio de Parasitología y Sanidad Acuícola, Carretera Iquitos-Nauta, Km 4.5, San Juan Bautista, Iquitos, Perú. germantiss1106@gmail.com
[2] Universidade Estadual do Maranhão (UEMA), São Luís 65081-400, Brazil.Maranhão, Brasil. alanasousa@professor.uema.br
[3] Universidade Estadual da Regiao Tocantina do Maranhão (UEMASUL), Cidade Universitária Paulo IV, São Luís, 65055-310, Maranhão-Brasil. diegoviana@professor.uema.br
[4] Universidad Científica del Perú (UCP), Av. Abelardo Quiñones KM 2.5 San Juan Bautista, Iquitos, Perú. josecruzguimaraes@gmail.com
[5] Universidad Nacional de San Martín, Laboratorio de Histopatología animal, Fundo Miraflores, Sector Ahuashiyacu, La Banda de Shilcayo, Tarapoto, San Martín, Perú. vhpuicon@unsm.edu.pe
[*] *For correspondence: vhpuicon@unsm.edu.pe*

Received: 04th November 2024. **Revised**: 04th December 2024. **Accepted**: 05th March 2025
Associate Editor: Francisco Ferreira

Citation/ citar este artículo como: Murrieta, G. A, de Sousa, AL, Viana, D. C, Cruz, J. L. and Puicón, V. H. (2025). Occurrence of camallanids (Nematoda: Camallanidae) in fish hosts from the Peruvian Amazonia. *Acta Biol. Colomb.*, *30*(2), 55-64. https://doi.org/10.15446/abc.v30n2.115945

ABSTRACT

Camallanids are nematodes that have been reported to parasitize different fish species in South America and can compromise the health of those species bred in captivity for fish farming and ornamental purposes. To date, in Peru, there are few studies related to camallanid parasitism in fish, so the main objective of this study was to report and identify species of this group of parasites present in 20 species of fish collected in the Peruvian Amazonia. Samples were analyzed through tissue and organ dissection methods for macroscopic evaluation and subsequent parasitic morphological and morphometric evaluation. Six species of camallanids were identified infecting the internal organs of analyzed fish: *Paracamallanus amazonensis*, *Spirocamallanus krameri*, *Spirocamallanus iheringi*, *Procamallanus (Spirocamallanus) inopinatus*, *Procamallanus (Spirocamallanus) juana* and *Procamallanus* (*Spirocamallanus*) *pintoi*.

Keywords: Amazonia, Camallanidae, nematodes infections, parasites, Peru.

RESUMEN

Los camalánidos son nemátodos que han sido reportados parasitando a diferentes especies de peces en Sudamérica, pudiendo comprometer la salud de aquellas especies criadas en cautiverio con fines piscícolas y ornamentales. A la fecha, en Perú existen escasos estudios relacionados al parasitismo de camalánidos en peces, por lo que el presente estudio tuvo como objetivo principal reportar e identificar a especies de este grupo de parásitos presentes en 20 especies de peces colectados en la Amazonía peruana. Las muestras se analizaron mediante métodos de disección de tejidos y órganos para su evaluación macroscópica y posterior evaluación morfológica y morfométrica. Como resultado, se identificaron seis especies de camalánidos infectando los órganos internos de los peces analizados: *Paracamallanus amazonensis*, *Spirocamallanus krameri*, *Spirocamallanus iheringi, Procamallanus (Spirocamallanus) inopinatus*, *Procamallanus (Spirocamallanus) juana* y *Procamallanus* (*Spirocamallanus*) *pintoi*.

Palabras clave: Amazonía, Camallanidae, infecciones por nemátodos, parásitos, Perú.

CC BY NC SA

INTRODUCTION

Among metazoan parasites, nematodes are recognized as important endoparasites that infect freshwater, brackish, and marine fish. They constitute a significant part of the parasitic fauna in different ecosystems around the world. The associations of these parasites with their fish hosts usually include larval or adult stages, as components of their parasitic communities (Gonçalves *et al.,* 2016; Almeida-Berto *et al.,* 2018). Some species can circulate freely through the intestine of the fish, being able to migrate to other sites and thus parasitize different organs, while others remain in a specific infection region. In general, they can particularly inhabit the digestive tract of hosts, but some species appear to prefer certain sites of infection and their pathogenicity varies depending on parasite load (Gonçalves *et al.,* 2016; Almeida-Berto *et al.,* 2018).

Captive-bred fish are frequently infected with helminth parasites from different groups, which can cause significant mortality rates in affected fish (Moravec, 1998). Within nematodes, species of the Camallanidae Raillet et Henry, 1915 are characterized by being blood-sucking parasites that can seriously damage affected fish (Moravec, 1998). The disrupts key physiological and metabolic processes of the host, interfering with feeding, sexual maturity, and reproduction, among others (Madhavi, 2003). As an example of the great diversity of this group of nematodes, more than 20 species of camallanids have been identified as parasitizing freshwater fish in South America: Kohn and Fernandes (1988); Reis *et al*. (2021); Ailán-Choke *et al*. (2021). There is interest in knowing more about the species of camallanids that parasitize host fish in the Peruvian Amazonia due to the great variety of species in this group of parasites. In this sense, the objective of this study was to record and identify the camallanid species parasitizing fish in the Peruvian Amazonia.

MATERIALS AND METHODS

Twenty fish species were collected on different excursions carried out by the research team of the "Laboratorio de Parasitología y Sanidad Acuícola" (LAPYSA) from "Instituto de Investigaciones de la Amazonía Peruana" (IIAP) between 2020 and 2022, in the Amazonas, Yavari, Tapiche and Nanay rivers, in Loreto, Peru.

All fishes belonged to specimens collected in natural environments (Table 1). Ten individuals of each fish species were collected (Table 2). The collection points were selected according to field trips organized by the staff of the LAPYSA. This study applied local set-net fishing to catch fish. Fish samples were taken alive, placed in plastic bags with water, and transported to LAPYSA- IIAP in Iquitos, Peru (3°49'01,81" S, 73°19'15,54"W). The taxonomic identification of fish species was based on García-Dávila *et al*. (2018) and García-Dávila *et al*. (2020). For parasitological analyses, fish were euthanized through a quick immersion in a 75 mg/L clove oil solution following the instructions given by Conselho Nacional de Controle de Experimentação Animal -CONCEA, Brazil (CONCEA, 2013).

Organs were placed in Petri dishes with distilled water, and with the aid of tweezers and needles, the tissue was examined by making fine cuts that allowed the examiner to observe inside them. In the presence of any parasites, these were examined with the aid of tweezers and needles and washed in a saline solution of 0.9 %, then, preserved in 70% ethanol for posterior taxonomic identification. For taxonomic identification, parasites were clarified in Amman Lactophenol (Amato *et al.,* 1991). For this, parasites were placed on a slide with a drop of Amman lactophenol, and then, they were observed under an optical microscope (Leica DM750®).

Microphotographs of parasites were made by using a microscope (Leica DM 750®) with an integrated digital camera (LEICA ICC50 W®), allowing clear identification of external structures and internal organs. The identification of the parasite was based on the morphological characteristics described by Moravec (1998) and Ramallo and Ailán (2017). Parasitological indices were calculated following Bush *et al*. (1997). The collected parasites were deposited in the Parasite Collection of the Peruvian Amazon Research Institute (IIAP).

RESULTS

Six species of camallanids were identified as infecting the visceral cavity and internal organs of the fish analyzed (Fig. 1). The species identified corresponded to: *Paracamallanus amazonensis* Ferraz & Thatcher, 1992, *Spirocamallanus krameri* Petter, 1974, *Spirocamallanus iheringi* Travassos, Artigas & Pereira, 1928, *Procamallanus (Spirocamallanus) inopinatus* Travassos, Artigas & Pereira, 1928, *Procamallanus (Spirocamallanus) juana* Ramallo & Ailán Choke, 2017 and *Procamallanus* (*Spirocamallanus*) *pintoi* Kohn & Fernandes, 1988. Details of the host, parasite species, and infection site are described below.

Paracamallanus amazonensis

Description: Small nematodes presenting a large buccal capsule, strongly sclerotized, yellowish to orange in color. The dorsal and ventral sides of the anterior part of the buccal capsule are provided with large tridents, exceedingly the posterior end of the capsule. The muscular esophagus is longer than the glandular one. Male specimens presented seven pairs of preanal caudal papillae, and six pairs of postanal papillae, presence of a large (right) spicule and a short (left) spicule, weakly sclerotized. Female specimens with vulva postequatorial, 1.8 – 2.2 mm from the posterior end of the body and with conical tail (Fig. 2d).

Measurements: males (N = 10) with body length 3.2 – 4.8 mm, maximum width 0.10 – 0.12 mm. Length of muscular

esophagus 0.62 – 0.68 mm, length of glandular esophagus 0.40 –0.48 mm. Tail 0.06 – 0.07 mm long. Females (N = 10) with body length 5.0 – 6.2 mm, maximum width 0.16 – 0.18 mm. Length of muscular esophagus 0.66 – 0.68 mm, length of glandular esophagus 0.60 – 0.66 mm. Tail 0.14 – 0.16 mm long.

Host: *Hypophthalmus celiae*
Infection site: intestine

Spirocamallanus krameri

Description: Presents an orange-brown buccal capsule; its inner surface is provided with spiral thickenings. Presents a muscular esophagus shorter than a glandular one. Male specimens with ten to 12 spiral thickenings in the buccal capsule; caudal papillae with four pairs of preanal, and six pairs of postanal papillae, presence of spicules well sclerotized, short, and almost equal in length. Female specimens presented 14-15 spiral thickenings in the buccal capsule, presence of numerous larvae in the body, vulva postequatorial, 7.2 – 14.0 mm from posterior end of body. The tail is conical, short, and with a rounded tip.

Measurements: males (N = 2) with body length 6.0 – 8.0 mm, maximum width 0.30 – 0.32 mm. Length of muscular esophagus 0.30 – 0.38 mm, length of glandular esophagus 0.50 – 0.56 mm. Tail 0.24 – 0.28 mm long. Females (N = 2) with body length 16.8 – 20.2 mm, maximum width 0.52 – 0.68 mm. Length of muscular esophagus 0.48 – 0.54 mm, length of glandular esophagus 0.60 – 0.72 mm. Tail 0.12 – 0.18 mm long.

Host: *Hoplerythrinus unitaeniatus, Hoplerythrinus malabaricus*
Infection site: intestine

Spirocamallanus iheringi

Description: This species presents a brownish buccal capsule; its inner surface is provided with spiral thickenings. Presents a muscular esophagus shorter than a glandular one. Male specimens with seven to nine spiral thickenings in the buccal capsule; caudal papillae with eight pairs of preanal, two pairs of adanals, and two pairs of postanal papillae, presence of spicules well sclerotized, simple, and unequal in length. Female specimens presented four to five spiral thickenings in the buccal capsule, presence of numerous larvae inside the body, vulva 2.2 – 2.5 mm from posterior end of body, the tail is conical, with a rounded tip.

Measurements: males (N = 2) with body length 12.4 – 14.0 mm, maximum width 0.34 –0.38 mm. Length of muscular esophagus 0.35 – 0.4 mm, length of glandular esophagus 0.80 – 0.84 mm. Tail 0.10 – 0.12 mm long. Females (N = 4) with body length 16.2 – 23.2 mm, maximum width 0.52 – 0.82 mm. Length of muscular esophagus 0.50 – 0.55 mm, length of glandular esophagus 0.9 – 1.2 mm. Tail 0.10 – 0.18 mm long.

Table 1. Fish hosts with their respective places of collection and geographical coordinates

Fish host	Place of collection	Region, Province and City	Geographic coordinates
Acestrorynchus falcirostris	Amazon river	Loreto, Maynas, Iquitos	3°41'39.1"S, 73°11'35.0"W
Megaleporinus trifasciatus	Amazon river	Loreto, Maynas, Iquitos	3°41'39.1"S, 73°11'35.0"W
Hoplerythrinus unitaeniatus	Amazon river	Loreto, Maynas, Iquitos	3°41'39.1"S, 73°11'35.0"W
Hoplias malabaricus	Amazon river	Loreto, Maynas, Iquitos	3°41'39.1"S, 73°11'35.0"W
Brycon amazonicus	Amazon river	Loreto, Maynas, Iquitos	3°41'39.1"S, 73°11'35.0"W
Mylossoma albiscopum	Amazon river	Loreto, Maynas, Iquitos	3°41'39.1"S, 73°11'35.0"W
Colossoma macropomun	Amazon river	Loreto, Maynas, Iquitos	3°41'39.1"S, 73°11'35.0"W
Pygocentrus nattereri	Amazon river	Loreto, Maynas, Iquitos	3°41'39.1"S, 73°11'35.0"W
Serrasalmus rhombeus	Amazon river	Loreto, Maynas, Iquitos	3°41'39.1"S, 73°11'35.0"W
Triportheus angulatus	Amazon river	Loreto, Maynas, Iquitos	3°41'39.1"S, 73°11'35.0"W
Hydrolycus scomberoides	Amazon river	Loreto, Maynas, Iquitos	3°41'39.1"S, 73°11'35.0"W
Plagioscion squamosissimus	Amazon river	Loreto, Maynas, Iquitos	3°41'39.1"S, 73°11'35.0"W
Brachyplatystoma vaillantii	Amazon river	Loreto, Maynas, Iquitos	3°41'39.1"S, 73°11'35.0"W
Hypophthalmus celiae	Amazon river	Loreto, Maynas, Iquitos	3°41'39.1"S, 73°11'35.0"W
Pseudoplatystoma punctifer	Amazon river	Loreto, Maynas, Iquitos	3°41'39.1"S, 73°11'35.0"W
Pseudoplatystoma tigrinum	Amazon river	Loreto, Maynas, Iquitos	3°41'39.1"S, 73°11'35.0"W
Corydoras leopardus	Yavari river	Loreto, Ramón Castilla, Santa Rosa	5°4'15.75"S, 73°52'53.21"W
Corydoras virginiae	Tapiche river	Loreto, Requena, Requena	5°4'15.75"S, 73°52'53.21"W
Corydoras splendens	Tapiche river	Loreto, Requena, Requena	5°4'15.75"S, 73°52'53.21"W
Corydoras multiradiatus	Nanay river	Loreto, Maynas, Iquitos	3°47'17.33"S, 73°22'28.77"W

Host: *Megaleporinus trifasciatus*
Infection site: intestine

Procamallanus (Spirocamallanus) inopinatus (Fig. 2)

Description: This species presents an orange-brown buccal capsule approximately as long as wide, its inner surface is provided with numerous, thin spiral thickenings (Fig. 2a). It presents a muscular esophagus distinctly shorter than a glandular one; both distinctly expanded at their posterior parts. Female specimens with 16-20 spiral thickenings in the buccal capsule, vulva postequatorial, 8.8 – 14.8 mm from posterior end of body Tail conical, relatively short (Fig. 2b). Male specimens with eight to 16 spiral thickenings in the buccal capsule; caudal papillae with four pairs of preanal and six pairs of postanal papillae, presence of spicules well sclerotized, short, and almost equal in length (Fig. 2c).

Measurements: males (N = 10) with body length 6.2 – 9.0 mm, maximum width 0.2 – 0.3 mm. Length of muscular esophagus 0.5 – 0.8 mm, length of glandular esophagus 0.4 – 0.8 mm. Tail 0.2 – 0.3 mm long. Females (N = 10) with body length 20.4 – 36.5 mm, maximum width 0.6 – 1.2 mm. Length of muscular esophagus 0.6 – 0.9 mm, length of glandular esophagus 0.7 – 1.6 mm. Tail 0.25 – 0.35 mm long.

Hosts: *Acestrorhynchus falcirostris, Brycon amazonicus, Colossoma macropomum, Hoplias malabaricus, Hydrolycus scomberoides, Mylossoma duriventre, Plagioscion squamosissimus, Pseudoplatystoma punctifer, Pseudoplatystoma tigrinum, Pygocentrus nattereri, Serrasalmus rhombeus, Triportheus angulatus.*

Infection sites: Intestine, stomach, visceral cavity, and pyloric caecum.

Procamallanus (Spirocamallanus) juana

Description: This species presents a slender and elongated body, an orange-brown buccal capsule; its inner surface is provided with spiral thickenings. Presents a muscular esophagus shorter than a glandular one. Female specimens presented four to seven spiral thickenings in the buccal capsule, vulva pre-equatorial, 6.5 – 7.5 mm from posterior end of the body. The tail is rounded. Male specimens with four to seven spiral thickenings in the buccal capsule; caudal papillae with three pairs of preanal, and three pairs of postanal papillae, presence of spicules well sclerotized, similar in shape but unequal in length.

Measurements: males (N = 2) with body length 9.2 – 13.0 mm, maximum width 0.18 – 0.28 mm. Length of muscular esophagus 0.52 – 0.58 mm, length of glandular esophagus 0.80 – 0.86 mm. Tail 0.14 – 0.22 mm long. Females (N = 2) with body length 16.0 – 24.2 mm, maximum width 0.30 – 0.38 mm. Length of muscular esophagus 0.64 – 0.66 mm,

Table 2. Parasitological indices of the camallanids identified in fish host species collected in the Peruvian Amazonia. AF = analyzed fish, PF = parasitized fish, P % = prevalence, I = intensity of infection, mI = mean intensity of infection, mA = mean abundance of infection.

Host	Parasite species	AF	PF	P %	I	mI	mA
Acestrorhynchus falcirostris	*Procamallanus* (*Spirocamallanus*) *inopinatus*	10	7	70	7	1	0.1
Megaleporinus trifasciatus	Spirocamallanus iheringi	10	6	60	6	1	0.1
Hoplerythrinus unitaeniatus	Spirocamallanus krameri	10	4	40	4	1	0.1
Hoplias malabaricus	Spirocamallanus krameri	10	4	40	4	1	0.1
Hoplias malabaricus	*P.* (*S.*) *inopinatus*	10	4	40	3	1	0.1
Brycon amazonicus	*P.* (*S.*) *inopinatus*	10	4	40	4	1	0.1
Mylossoma duriventre	*P.* (*S.*) *inopinatus*	10	3	30	3	1	0.1
Colossoma macropomum	*P.* (*S.*) *inopinatus*	10	2	20	2	1	0.1
Pygocentrus nattereri	*P.* (*S.*) *inopinatus*	10	6	60	6	1	0.1
Serrasalmus rhombeus	*P.* (*S.*) *inopinatus*	10	5	50	5	1	0.1
Triportheus angulatus	*P.* (*S.*) *inopinatus*	10	5	50	5	1	0.1
Hydrolycus scomberoides	*P.* (*S.*) *inopinatus*	10	3	30	3	1	0.1
Plagioscion squamosissimus	*P.* (*S.*) *inopinatus*	10	3	30	3	1	0.1
Brachyplatystoma vaillantii	Procamallanus (Spirocamallanus) juana	10	3	30	4	1.3	0.4
Hypophthalmus celiae	Paracamallanus amazonensis	10	9	90	27 (1-3)	3	0.3
Pseudoplatystoma punctifer	*P.* (*S.*) *inopinatus*	10	3	30	3	1	0.1
Pseudoplatystoma tigrinum	*P.* (*S.*) *inopinatus*	10	4	40	4	1	0.1
Corydoras leopardus	*Procamallanus* (*Spirocamallanus*) *pintoi*	10	10	100	20 (1-2)	2	0.2
Corydoras virginiae	*P.* (*S.*) *pintoi*	10	10	100	24 (1-2)	2.4	0.24
Corydoras splendens	*P.* (*S.*) *pintoi*	10	6	60	10	1.66	0.166
Corydoras multiradiatus	*P.* (*S.*) *pintoi*	10	5	50	20 (1-4)	4	0.4

length of glandular esophagus 0.72 – 0.92 mm. Tail 0.10 – 0.14 mm long.

Host: *Brachyplatystoma vaillantii*

Infection site: intestine

Procamallanus* (*Spirocamallanus*) *pintoi (Fig. 3)

Description: medium size nematodes with finely striated cuticle. Esophagus divided. Its anterior muscular portion is club-shaped, posterior glandular part is almost cylindrical, longer than the muscular portion (Fig. 3a). Buccal capsule with inner spiral thickenings (Fig. 3b). Female specimens with nine-ten spiral thickenings, vulva postequatorial 6.8 – 7.8 mm from posterior end of body, and tail with elongated digitiform termination (Fig. 3c). Male specimens with six to eight spiral thickenings in the buccal capsule; caudal papillae with four pairs of preanal, and two of postanal papillae, spicules short and similar (Fig. 3d). The tail is conical.

Measurements: males (N = 10) with body length 3.0 – 4.6 mm, maximum width 0.16 – 0.18 mm. Length of muscular esophagus 0.24 – 0.26 mm, length of glandular esophagus 0.55 – 0.58 mm. Tail 0.10 – 0.12 mm long. Females (N = 10) with body length 22.6 – 24.2 mm, maximum width 0.82 – 1.12 mm. Length of muscular esophagus 0.30 – 0.36 mm, length of glandular esophagus 0.90 – 1.40 mm. Tail 0.28 – 0.34 mm long.

Hosts: *Corydoras leopardos. Corydoras virginiae. Corydoras splendens. Corydoras multiradiatus.*

Infection site: intestine

Parasitological indices in fish hosts collected in the Peruvian Amazon are presented in Table 2.

DISCUSSION

Paracamallanus amazonensis was discovered and described for the first time parasitizing the intestine of *Hypophthalmus edentatus* collected in the Solimões River, in the Brazilian Amazon (Ferraz and Thatcher, 1992). This is the first study to report parasitological indices for this nematode species. No parasitic indices values are mentioned in the original description of the species (Ferraz and Thatcher, 1992). Additionally, the present study represents the second record of this parasite parasitizing a different fish species in the Neotropical region, as well as the first record for *H. celiae* and the first report of this parasite for the Peruvian Amazon, expanding its geographic distribution range and the number of known hosts.

Spirocamallanus krameri was reported for the first time in *Hoplerythrinus unitaeniatus* collected in a market of Cayenne, French Guiana (Petter, 1974). Later, this parasite was described by Moravec (1998) from *H. unitaeniatus* collected

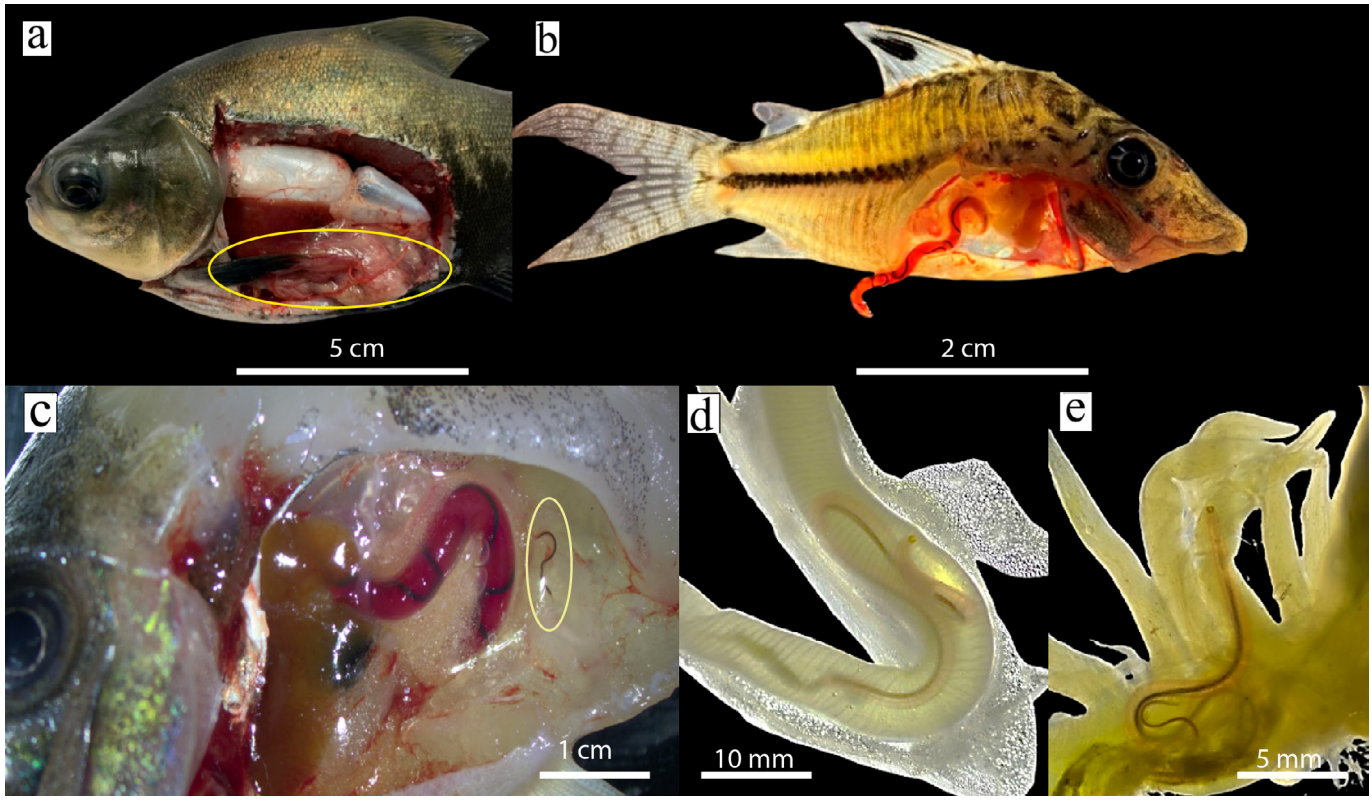

Figure 1. a. *Procamallanus* (*Spirocamallanus*) *inopinatus* in the visceral cavity of *Colossoma macropomum*. b. *Procamallanus* (*Spirocamallanus*) *pintoi* infecting *Corydoras leopardus*. c. Female and male specimens of *Procamallanus* (*Spirocamallanus*) *pintoi*. Yellow circle indicates the presence of a male specimen. d. Intestine of *Megaleporinus trifasciatus* parasitized by *Spirocamallanus iheringi*. e. Pyloric caecum of *Pygocentrus nattereri* parasitized by *Procamallanus* (*Spirocamallanus*) *inopinatus*.

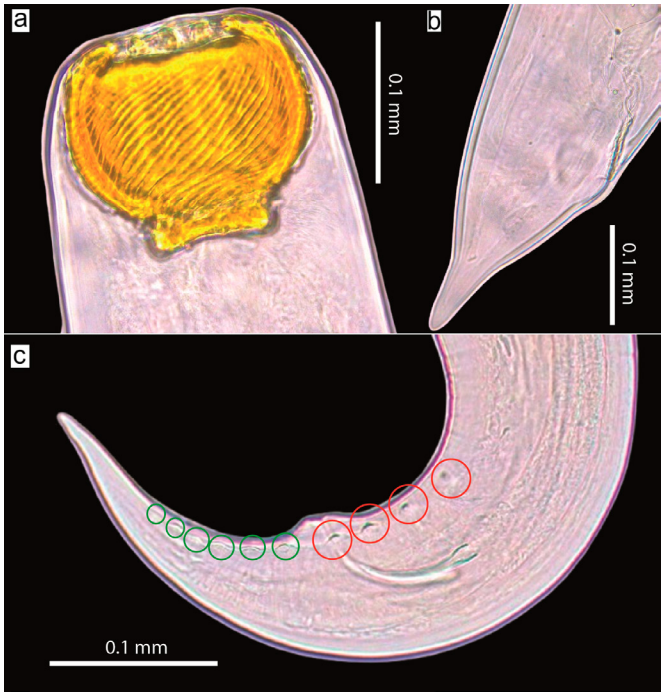

Figure 2. *Procamallanus* (*Spirocamallanus*) *inopinatus.* a. Buccal capsule. b. Tail of a female specimen. c. Tail of a male specimen. Red circles indicate pre-anal genital papilla, and green circles indicate post-anal genital papilla.

in Venezuela. This species was reported for the first time in Brazil, in hosts captured in the State of Pará (Pinheiro *et al.,* 2020). Later, this parasite was reported parasitizing the intestine of *Bryconops* cf. *affinis* witha prevalence of 15.6 % and *Saxatilia brasiliensis* (Bloch, 1792) with a prevalence of 3.12 % from the Munim River basin in Brazil (Cárdenas *et al.,* 2024). In the present study, this parasite is reported for the first time in Peru, in specimens of *H. malabaricus,* with a 40% prevalence, higher than that reported in other hosts. This result increases the geographical distribution of this parasite and the number of hosts known.

Spirocamallanus iheringi has been reported parasitizing *Schizodon nasutus* Kner, 1858 (Anostomidae) from Pirassununga, São Paulo, Brazil (Pinto and Noronha, 1976), Moravec (1998) reported this nematode parasitizing the intestine and pyloric caeca of *Salminis hilarii* Valenciennes, 1850*, Leporinus copelamdii* Steindachner, 1875*, L. elongatus* (Valenciennes, 1850)*, L. fasciatus* (Bloch, 1794)*, L. octofasciatus* Steindachner, 1915*, Leporinus* sp., *Schizodon borelli* (Boulenger, 1900)*, S. fasciatus* Spix & Agassiz, 1829*, S. nasutus* Kner, 1858*, H. malabaricus* and *Pseudopimelodus zungaro* (Humbolt, 1821) all from the Paraná River basin in Brazil. Feltran *et al*. (2004) reports only values of parasitic prevalence in *L. friderici* (Bloch, 1794) and *L. obiusidens* (Valenciennes, 1837) from Brazil (2 and 4 % respectively). In the present study, *M. trifasciatus* is added as the new host for this parasite, with higher prevalence values than the previously reported in other studies. Additionally, Peru is added as a new locality record for this parasite.

Procamallanus (*Spirocamallanus*) *inopinatus* is a nematode with low specificity that has been recorded in more than 80 species of tropical fish corresponding to 19 families and five taxonomic orders (Neves *et al.,* 2020). In Central Amazon it has been reported for *Brycon amazonicus* (Spix & Agassiz, 1829) captured in Lake Catalão (Andrade *et al.,* 2001), in the Juruá River (Fernandez, 2010), in specimens of *P. punctifer* acquired in Manaus markets (Lopes *et al.,* 2009), in *P. nattereri* captured in the Rio Solimões (Morais, 2011), in *Cichla monoculus* Agassiz, 1831 from flooded lakes of the Solimões River (Santana, 2013). For fish from the Peruvian Amazonia, this nematode has been reported in *P. nattereri* (Castro- Saavedra y Magalhaes-Pacaya, 2022), *T. angulatus* (Rengifo-Chota *et al.,* 2022), and in *P. punctifer* and *P. tigrinum* from the Belén Market, in Iquitos, Loreto-Peru (Tuesta, 2021). In the present study, *P.* (*S.*) *inopinatus* was recorded in 12 of the 20 hosts analyzed, thus reaffirming its presence in various fish hosts. The parasitological indices reported for hosts from the Peruvian Amazon are similar to the those found in this study.

Procamallanus (*Spirocamallanus*) *juana* was discovered and described in Argentina, from *Pimelodus albicans* (Valenciennes, 1840) with a prevalence of 75 % and mean intensity of infection of 3.3 nematodes per fish, and *Pimelodella gracilis* (Valenciennes, 1835) with a prevalence of 75 % and mean intensity of infection of 4 nematodes per fish (Ramallo y Alain- Choke, 2017). In the present study, this parasite is reported for the second time in South America and for the first time in the Peruvian Amazon infecting *B. vaillantii*, reporting a lower prevalence of 30 % and a lower mean intensity of infection of 1 parasite per fish. Additionally, *B. vaillantii* is presented as a new host for this parasite. To date, this nematode has been recorded only in species belonging to the Pimelodidae, suggesting its specificity for this taxonomic family.

Procamallanus (*Spirocamallanus*) *pintoi* has been reported infecting the intestine of *Corydoras paleatus* (Jenys, 1842) and *C. aeneus* (Gill, 1858) from the Paraná River basin in Brazil (Moravec, 1998). Ito *et al*. (2005) analyzed the ecological aspects of *P.* (*S.*) *pintoi* from five reservoirs in Paraná state, reporting a prevalence of 78 % and mean intensity of infection of 2.04 parasites per fish. In Colombia, *P.* (*S.*) *pintoi* was reported to parasitize *C. metae* Eigenmann, 1914 with a prevalence of 66 % and a mean intensity of infection of 1.60 (Piñeros *et al.,* 2017). In Argentina, this camallanid has been reported infecting the intestine of *C. miracanthus* Regan, 1921 and *C. paleatus* from Bermejo and Juramento River basins, in Argentina (Ailán-Choke *et al.,* 2018). For Peru, the first study reporting the parasitism of camallanids in callychthids was the research conducted by Morey and Florindez (2018) where *P.* (*S.*) *pintoi* was identified in the intestine of six fish species. These authors also recorded high prevalences greater than 50 % in *C. leopardus, C. virginiae,* and *C. splendens*. In the present study, the prevalences of

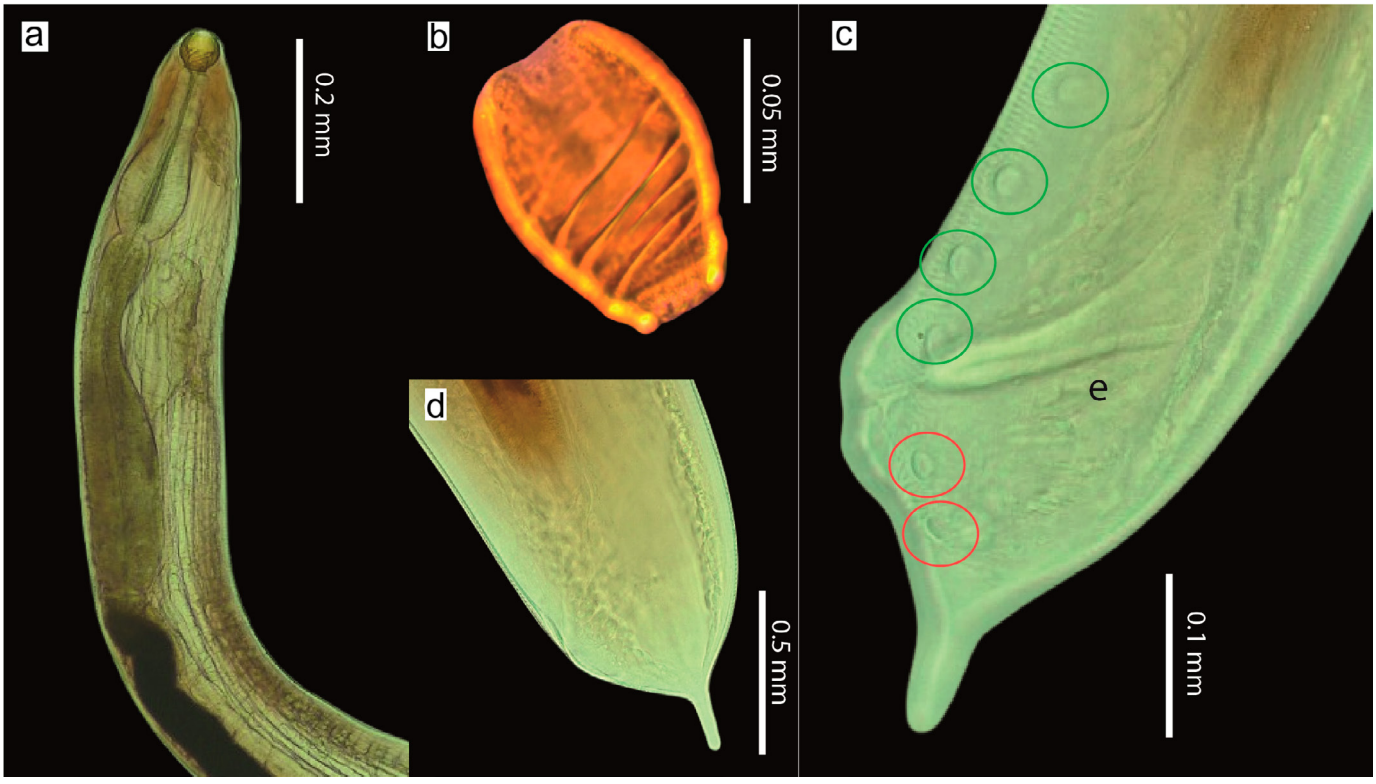

Figure 3. *Procamallanus* (*Spirocamallanus*) *pintoi.* a. Ventral view of the body. b. Buccal capsule. c. Tail of a female specimen. d. Tail of a male specimen. Green circles indicate pre- anal genital papilla and red circles indicate post-anal genital papilla. e = spicules.

callichthyids analyzed varied from 50 to 100 %. Additionally, the findings of the present study and the ones reported in other countries confirm the specificity of *P.* (*S.*) *pintoi* for species of the Callichthyidae.

Given that 18 species of callichthyids have been reported in the Peruvian Amazon as species of ornamental importance (García-Dávila *et al.,* 2020), additional studies with species of this family are necessary to continue with the knowledge of the parasitic diversity in callichthyids of the Peruvian Amazon, thus increasing the number of known hosts for this parasite.

CONCLUSION

P. amazonensis is reported for the first time in the Peruvian Amazon, on a new host, *H. celiae*. *Spirocamallanus krameri* is recorded for the first time in Peru, extending its known geographic range.

Spirocamallanus iheringi is reported for the first time in Peru, with *M. trifasciatus* as a new host. *Procamallanus (Spirocamallanus) juana* is reported for the second time in South America and for the first time in Peru, adding *B. vaillantii* to the known host list. Finally, this study highlights the diversity of camallanids paraziting fish hosts belonging to different orders and families, emphasizing the importance of continuing studies on helminth parasites in Peruvian Amazon fish

ACKNOWLEDGMENTS

The authors are grateful to the ACUIPRO project of the IIAP for the support provided in conducting this study.

CONTRIBUTIONS A.S.:

G.A.M.M., A.L.S and D.V.C: Data curation; Formal analysis; Investigation; Writing - original draft - review &editing; Prepared all figures.

J.L.C.G and V.H.P.N.G: Investigation, Data curation; Formal analysis; Writing - original draft - review &editing

CONFLICT OF INTEREST

The authors declare that they have no conflicts of interest.

REFERENCES

Ailán-Choke, L. G., Ramallo, G. and Davies, D. (2018). Further study on *Procamallanus (Spirocamallanus) pintoi* (Nematoda: Camallanidae) in *Corydoras paleatus* and *Corydoras micracanthus* (Siluriformes: Callichthyidae) from Salta, Argentina, with a key to congeneric species from the Neotropical Realm. *Acta Parasitologica, 63*(3), 595–604. https://doi.org/10.1515/ap-2018-0068

Ailán-Choke, L. G. and Pereira, F. B. (2021). Deep in the systematics of Camallanidae (Nematoda): Using integrative taxonomy to better understand the phylogeny and consistency of diagnostic traits. *Parasitology, 148*(8), 962–974. https://doi.org/10.1017/S0031182021000706

Almeida-Berto, M.C., Monteiro, C. and Brasil-Sato, M. (2018). Parasitic helminths of the non-native serrasalmid fish *Metynnis lippincottianus* from the Três Marias Reservoir, Southeast Brazil. *Revista Brasileira de Parasitologia Veterinária, 27*(3), 289-94. https://doi.org/10.1590/S1984-296120180040

Amato, J., Boeger, W. and Amato, S. (1991). Protocolos para laboratório coleta e processamento de parasitas do pescado. Imprensa Universitária da Universidade Federal do Rio de Janeiro. Rio de Janeiro.

Andrade, S., Malta, J. and Ferraz, E. (2001). Fauna parasitológica de alevinos de matrinxã, *Brycon cephalus* (Günther, 1869) coletados nos rios Negro e Solimões, na Amazônia Central. *Acta Amazonica*, *31*(2), 263-273. https://doi.org/10.1590/1809- 43922001312273

Bush, A. O., Lafferty, K. D., Lotz, J. M. and Shostak, A. W. (1997). Parasitology meets ecology on its own terms: Margolis *et al*. revisited. *The Journal of parasitology, 83*(4), 575-583. https://doi.org/10.2307/3284227

Cáceda, M., Puicón, V. H., Smales, L. R. and Murrieta, G. A. (2024). Histopathological lesions in *Corydoras* spp. (Siluriformes: Callychthyidae) caused by *Procamallanus (Spirocamallanus) pintoi* (Nematoda: Camallanidae) from Iquitos, Peru. *Brazilian Journal of Veterinary Pathology, 17*(3), 1–10. https://doi.org/10.24070/bjvp.1983- 0246.v17i3p1-10

Cárdenas, M. Q., Silva, M. L., Viana, D. C., Cohen, S. C. and Ottoni, F. P. (2024). Nematofauna of *Bryconops cf. affinis* (Characiformes, Iguanodectidae) and *Saxatilia brasiliensis* (Cichliformes, Cichlidae) from the Munim River basin, Northeastern Brazil. *Revista Brasileira de Parasitologia Veterinária, 33*(3), e011224. https://doi.org/10.1590/s1984-29612024051

Castro-Saavedra, P. B. y Magalhaes-Pacaya, R. A. (2022). *Ectoparásitos y endoparásitos presentes en Pygocentrus nattereri (Kner, 1858) (Characiformes, Serrasalmidae) "piraña roja" comercializados en el mercado Belén, Iquitos-Perú* [Tesis de licenciatura]. Universidad Nacional de la Amazonía Peruana. https://repositorio.unapiquitos.edu.pe/handle/20.500.12737/8878

CONCEA. 2013. Diretrizes da Prática de Eutanásia do Conselho Nacional de Controle de Experimentação Animal- CONCEA. Ministério da Ciência, Tecnologia e Inovação, Brasília.

Echevarria Matos, A. M. (2023). *Detección de parásitos en la especie amazónica Manitoa (Brachyplatystoma vaillantii) de vida silvestre en expendio en los mercados Belén, Itinerario y Modelo de la Ciudad de Iquitos–Perú* [Tesis de maestría]. Universidad Peruana Cayetano Heredia. https://repositorio.upch.edu.pe/handle/20.500.12866/14688

Feltran, BR., Júnior, O. M., Pinese, J. F. and Takemoto, R. M. (2004). Prevalência, abundância, intensidade e amplitude de infecção de nematóides intestinais em Leporinus friderici (Bloch, 1794) e L. obtusidens (Valenciennes, 1836) (Pisces, Anostomidae), na represa de Nova Ponte (Perdizes, MG). *Revista Brasileira de Zoociências, 6*(2). https://periodicos.ufjf.br/index.php/zoociencias/article/view/24191

Fernandez Piedade, M. T. (2010). *Composição e estrutura das infracomunidades parasitárias de Brycon amazonicus (Spix y Agassiz, 1829) explotada nos rios Juruá e Purus, tributários do rio Solimões e desembarcada em Manaus no Estado do Amazonas, Brasil* [Tesis de doctorado]. Instituto Nacional de Pesquisas da Amazônia. https://www.oasisbr.ibict.br/vufind/Record/BRCRIS_e3c7bdb0d367e9df1a175b14395624c2

Ferraz, E. and Thatcher, V. (1992). *Paracamallanus amazonensis* sp. n. (Nematoda: *Camallanidae*) um parasita de bagre, *Hypophthalmus edentatus* (Pisces: Hypophthalmidae) da Amazônia Brasileira. *Amazoniana: Limnologia et Oecologia Regionalis Systematis Fluminis Amazonas*, 12, 1-6.

García-Dávila, C., Sánchez, H., Flores, M., Mejia, J., Angulo, C., Castro-Ruiz, D., Estivals, G., García, A., Vargas, G., Nolorbe, C., Núñez, J., Mariac, C., Duponchelle, F. y Renno, J. F. (2018). *Peces de consumo de la Amazonía peruana*. Instituto de Investigaciones de la Amazonía Peruana (IIAP). Iquitos.

García-Dávila, C., Estivals, G., Mejia, J., Flores, M., Angulo, C., Sánchez, H., Nolorbe, C., Chuquipiondo, C., Castro-Ruiz, D., García, A., Ortega, H., Pinedo, L., Oliveira, C., Römer, U., Mariac, C., Duponchelle, F. y Renno, J.-F. (2020). *Peces ornamentales de la Amazonía peruana*. Instituto de Investigaciones de la Amazonía Peruana (IIAP). Iquitos.

Gonçalves, R. A., Oliveira, M. S., Neves, L. R. and Tavares, M. (2016). Seasonal pattern in parasite infracommunities of *Hoplerythrinus unitaeniatus* and *Hoplias malabaricus* (Actinopterygii: Erythrinidae) from the Brazilian Amazon. *Acta Parasitologica*, *61*(1), 119-129. http://dx.doi.org/10.1515/ap-2016-0016

García-Tumbalobos, R. O. (2021). *Identificación de nematodos en Pygocentrus nattereri "piraña" (Serrasalmidae) y Pimelodus blochii "bagre" (Pimelodidae) procedentes de Iquitos, Loreto* [Tesis de licenciatura]. Universidad Ricardo Palma. https://hdl.handle.net/20.500.14138/4204

Iannacone, J. A., López, E. N. and Alvariño, L. (2000). *Procamallanus (Spirocamallanus) inopinatus* Travassos, Artigas et Pereira, 1928 (Nematoda: Camallanidae) endoparasito de *Triportheus angulatus* (Spix, 1829) (Characidae) en la laguna de Yarinacocha, Ucayali-Perú. *Biología Pesquera, 28,* 37–43. https://doi.org/10.21703/0067-8767.2000.28.2610

Ito, K. F., Moreira, S. T., Takemoto, R. M. and Pavanelli, G. C. (2005). Ecological aspects of *Procamallanus (Spirocamallanus) pintoi*, parasite of *Corydoras paleatus*

(Jenyns, 1842) (Siluriformes: Callichthyidae) in reservoirs of the State of Parana, Brazil. *Acta Scientiarum Biological Sciences, 27*(3), 239–242. Kohn, A. and Fernandes, B. (1988). Helminth parasites of fishes from the hydroeletric power station of eletrosul (Brazil). I: *Procamallanus petterae* n. sp. and *Spirocamallanus pintoi* n. sp. (Nematoda, Camallanidae) from the reservoir of Salto Osório. *Memorias do Instituto Oswaldo Cruz*, *83*: 293-298. https://doi.org/10.1590/S0074-02761988000300005

Lopes, L., Varella, A. and Malta, J. (2009). Metazoan parasites of *Pseudoplatystoma puncifer* (Linnaeus, 1766) and *Pseudoplatystoma tigrinum* (Spix & Agassiz, 1829) (Siluriformes: Pimelodidae) of the Central Amazon Basin, Brazil. *Biologia Geral e Experimental*, *9*, 3-15.

Madhavi, R. (2003). Metazoan parasites in fishes. In: Aquaculture Medicine, (I.S. Bright Singh, S.S. Pai, R. Philip and A Mohan das, Eds.). Cochin University of Science and Technology, Cochin. pp. 64-68.

Morais, A. (2011). *Biodiversidade de parasitos da piranha vermelha Pygocentrus nattereri (Kner, 1858) (Characiformes; Serrasalmidae) e sua avaliação como bioindicadores na Amazônia Central* [Tesis de doctorado]. Instituto Nacional de Pesquisas da Amazônia. https://repositorio.inpa.gov.br/handle/1/11480

Moravec, F. (1998). Nematodes of freshwater fishes of the Neotropical region. Institute of Parasitology. Academy of sciences of the Czech Republic, Prague.

Morey, G. and Florindez, F. (2018). *Procamallanus (Spirocamallanus) pintoi* (Kohn and Fernandes, 1988) (Nematoda: Camallanidae) infecting species of Callichthyidae from the Peruvian Amazon. *Bulletin of the European Association of Fish Pathologists, 38*(6), 249–253.

Neves, L. R., Silva, L. M., Florentino, A. C. and Tavares-Dias, M. (2020). Distribution patterns of *Procamallanus (Spirocamallanus) inopinatus* (Nematoda: Camallanidae) and its interactions with freshwater fish in Brazil. *Revista Brasileira de Parasitologia Veterinária, 29*(4). https://doi.org/10.1590/S1984-29612020092

Ortiz-Arias, N. M., Martínez, M. E., Chaupe, N. N., de Sousa, A. L. and Murrieta, G. A. (2023). Intestinal endoparasitism in *Corydoras multiradiatus* (Siluriformes: Callichthyidae) in Iquitos, Loreto-Peru. *Revista de Ciências Agroveterinárias, 22*(4), 631–635. https://doi.org/10.5965/223811712242023631

Petter, A. J. (1974). Deux nouvelles espèces de nématodes Camallanina parasites de *Hoplerythrinus unitaeniatus* (Characidae, Cypriniformes) en Guyane ; création d'une nouvelle famille: les Guyanemidae (Dracunculoidea). *Bulletin du Muséum National d'Histoire Naturelle, Paris, Série 3, Zoologie, 156,* 803–812. https://doi.org/10.5962/p.277434

Piñeros, A., Quintana, Y. y Olaya, V. (2017). Parámetros de infección de *Procamallanus (Spirocamallanus)* cf. *pintoi* en *Corydoras metae* de Villavicencio, Colombia. *La Técnica, 18*, 49-57. https://doi.org/10.33936/la_tecnica.v0i18.806

Pinheiro, R., Cardoso, P., Monks, S., Santos, J. and Giese, E. (2020). First record of *Spirocamallanus krameri* (Nematoda: Camallanidae) in Brazil: morphological review. *Anais da Academia Brasileira de Ciências*, *92*(suppl 2), e20180721. https://doi.org/10.1590/0001-3765202020180721

Pinto, R. M. and Noronha, D. (1976). *Procamallanus brasileiros* (Nematoda, Camallanoidea): Considerações finais, com chave para determinação das espécies. *Memórias do Instituto Oswaldo Cruz, 74*(3-4), 323–339. https://doi.org/10.1590/S0074-02761976000300011

Ramallo, G. and Ailán, L. (2017). Observations on two *Procamallanus (Spirocamallanus)* species (Nematoda: Camallanidae) from freshwater fishes in Argentina, including description of *Procamalla*nus *(Spirocamallanus) juana* sp. nov., *Zootaxa*, *4323*: 286-294. https://dx.doi.org/10.11646/zootaxa.4323.2.12

Reis, M. S., Santos, C. P., Nunes, J. L. S. and Mugnai, R. (2021). Checklist of nematodes parasitizing fish in the Brazilian Amazon. Journal of Helminthology, 95, e75. https://doi.org/10.1017/S0022149X21000729

Rengifo-Chota. H. D., Cubas, R., Tuesta, C. A. and Morey, G. A. (2022). Parasitic metazoan of *Triportheus angulatus* (Spix & Agassiz, 1829) "Sardina" acquired in the market "Belén" Iquitos, Peru. *Neotropical Helminthology, 16*, 37-48.

Rivadeneyra, N. L., Mertins, O., Cuadros, R. C., Malta, J. C., de Matos, L. V. and Mathews, Santana, H. (2013). A fauna parasitária de *Cichla monoculus* (Spix & Agassiz, 1831) (Perciformes: Cichlidae) de lagos de várzea da Amazônia Central, Brasil. [Tesis de maestría]. Universidade Federal do Amazonas. https://tede.ufam.edu.br/handle/tede/7227

Selis-Pinchi, L. E. (2022). *Endoparásitos con potencial zoonótico en cinco especies de peces de consumo comercializados en el puerto "Don José" - Iquitos* [Tesis de maestría]. Universidad Nacional de la Amazonía Peruana. https://repositorio.unapiquitos.edu.pe/handle/20.500.12737/8227

Tuesta, C. (2021). *Composición de endoparásitos en Pseudoplatystoma punctifer (Castelnau, 1855) "doncella" y Pseudoplatystoma tigrinum (Valenciennes, 1840) "tigre zungaro" del mercado Belén, Iquitos-Perú* [Tesis de pregrado]. Universidad Nacional de la Amazonía Peruana. https://repositorio.unapiquitos.edu.pe/handle/20.500.12737/7659